

# The effect of concentrated growth factors on ridge augmentation

## Introduction

The bony defects can be developed by periodontal disease, tooth loss, trauma and infection. Guided bone generation (GBR) is one of popular methods to augment bone in the site of implant placement.<sup>1</sup> For successful gain from GBR procedure, primary wound closure, angiogenesis, space maintenance and clot stabilization are prerequisites.<sup>2&3</sup> Resorbable or non-resorbable membrane is required to exclude soft tissue ingrowth and space maintenance. In addition, variable concentrated platelet making methods have been introduced to accelerate new bone formation.<sup>4-7</sup> The aim of this case report is to evaluate the effect of concentrated growth factor (CGF) mixed with bone graft and CGF barrier membrane to accelerate bone formation.

## Historical background of platelet aggregation

Growth factors are proteins which regulate in the complex processes of wound healing. Growth factors play a main role on cell migration, cell proliferation and angiogenesis in tissue regeneration phase.<sup>8</sup> These growth factors are mainly located in blood plasma and platelets. So platelet aggregate has been widely used to accelerate tissue regeneration and repair in dental and medical area. As first generation of platelet concentrate, platelet rich plasma (PRP) and Platelet rich in growth factor (PRGF) was well known. PRP was introduced by Marx.<sup>9</sup> But the effect of PRP shows weak effect regarding on hard tissue regeneration.<sup>10</sup> PRGF was introduced by Anitua.<sup>11</sup> PRGF is very similar with PRP. PRP and PRGF need chemical additives as Calcium Chloride and bovine thrombin to make gel condition. These methods are technical sensitive to take platelet aggregation from test tube with pipetting procedure.

As second generation of platelet aggregation, Platelet rich fibrin (PRF) was first introduced by Choukroun.<sup>12</sup> PRF is a fibrin-rich gel produced with fresh venous blood taken from a patient's vein. The PRF protocol is simple and predictable. Patient's venous blood sample is taken without anticoagulant in 10-mL tubes which are immediately centrifuged at 3000 rpm (approximately 400g according to our calculations) for 10 minutes. After 10 minutes centrifugation, a fibrin rich gel with aggregated platelet is obtained in the middle of the tube, just between the red corpuscles at the bottom and platelet poor plasma at the top. The Fibrin rich gel accelerates new bone formation and soft tissue healing thanks to thanks to the release of growth factors.<sup>13-14</sup> PRF protocol doesn't need biochemical additives like bovine thrombin and chemical additives as Calcium Chloride to make gel condition. So PRF is free from the concern of cross-contamination.

Concentrated growth factors (CGF) was first developed by Sacco.<sup>7</sup> CGF is produced by the centrifugation of venous blood as same as PRF. However, the technique is different on centrifugation speed.

Unlike PRF, CGF use variable rpm from 2400-2700 rpm to separate cells in the venous blood, therefore, results in fibrin rich blocks that are much larger, denser and richer in GF than common PRF. This shows better regenerative capacity and higher versatility when using the fibrin rich block.

According to Professor Rodella at University of Brescia, Department of Biomedical Sciences and Biotechnologies, CGF shows higher tensile strength, more growth factors, higher viscosity and higher adhesive strength than PRF. So surgeons can use CGF as barrier membrane to accelerate soft tissue healing or be mixed with bone graft to accelerate

new bone formation. (Fig 1-5) CGF doesn't require any chemical or allergenic additives, such as bovine thrombin or anticoagulants, so is free from viral transmission disease.



Figure 1: Special centrifuge for the preparation of CGF (Medifuge, Silfradent srl, Sofia, Italy), one step protocol is needed to obtain CGF from patient's venous blood sample.



Figure 2: Concentrated growth factors are aggregated in the middle layer after 12 minutes special centrifugation using variable speed. Red corpuscles is separated from fibrin clot with scissor before use.

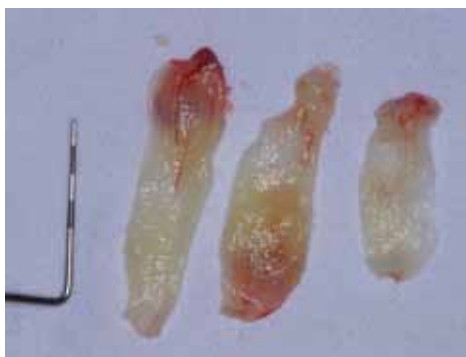
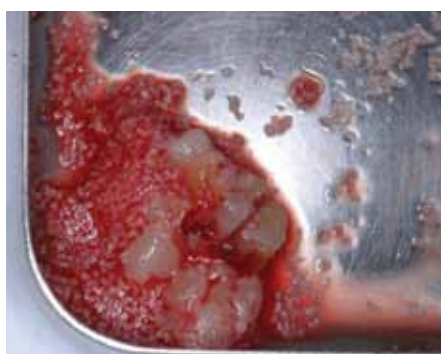

Figure 3 & 4: Very dense barrier membrane made by CGF fibrin block. This membrane is denser than PRF barrier membrane



Figure 5: Small pieces of CGF mixed with bone graft to accelerate new bone formation. This phase is gel conditioned, so it is easy to graft into the bony defect.



## Case series report

### 1. Case report 1 : Use of CGF for intern sinus elevation and GBR

49 years old man visited at our department complained the missing # 16 tooth. He wanted implant supported prosthesis. The tooth was extracted 2 months ago at private clinic. No specific medical and dental past history were not detected. Standard periapical radiogram showed extraction bony defect and low bone height. (Fig 6)

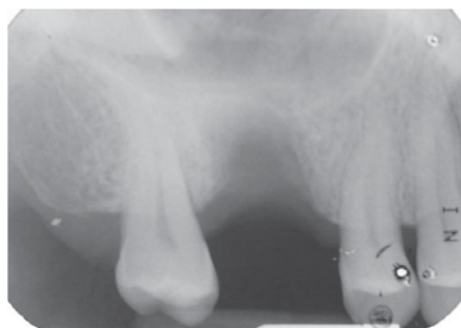

Figure 6: Standard periapical radiogram showing extraction bony defect and low bone height at # 16

Cefditoren pivoxil (Meiact®; Boryung Pharm., Seoul, Korea) 300mg was given to patient as preventive antibiotics one day before surgery. This antibiotic was continued for 7 days after surgery. 2% lidocaine (with 1:100,000 epinephrine) was injected and full thickness flap was elevated to expose extraction bony defect. Hydrodynamic piezoelectric internal sinus elevation (HPISE) was applied to elevated sinus membrane after complete removal of granulation tissue at extraction socket. (Fig 6) HPISE

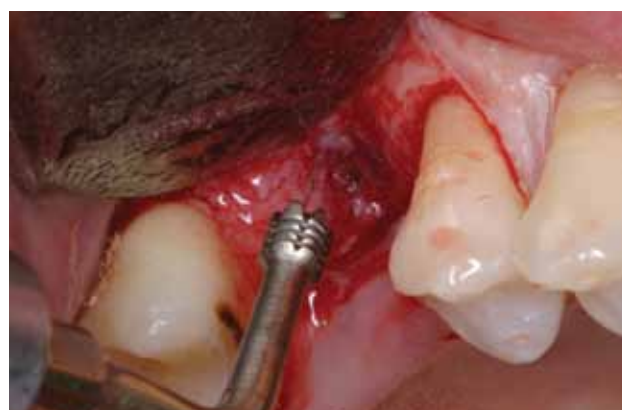

Figure 7: Thanks to selective cut of piezosurgical device, HPISE tip penetrated sinus floor without a damage to sinus membrane. Sinus membrane was elevated up to 5mm high before implant placement by hydraulic pressure.

insert was connected with ultrasonic piezoelectric surgical device (Surgybone®, Silfradent srl, Sofia, Italy). After breaking sinus floor with HPISE insert, hydraulic pressure was applied for 10-20 seconds to elevate sinus membrane. (Fig 7)

20cc venous blood was taken to prepare 2 pieces of CGF. (Fig 8)



Figure 8: Thanks to selective cut of piezosurgical device, HPISE tip penetrated sinus floor without a damage to sinus membrane. Sinus membrane was elevated up to 5mm high before implant placement by hydraulic pressure.

One piece of CGF was inserted under the elevated sinus membrane to accelerate new bone formation in the new compartment of sinus. The other was compressed with finger on the wet gauze to make barrier membrane. Implant (11.5mm high and 4.7mm wide, Scewplant implant, ImplantDirect LLC, USA) was placed and bovine bone (Bio-Cera™, Osctoc, Korea) was grafted to augment vertical and horizontal defect around implant. CGF barrier was covered on the graft to accelerate new bone formation and exclude soft tissue ingrowth (Fig 9-11). Tension free suture was done.

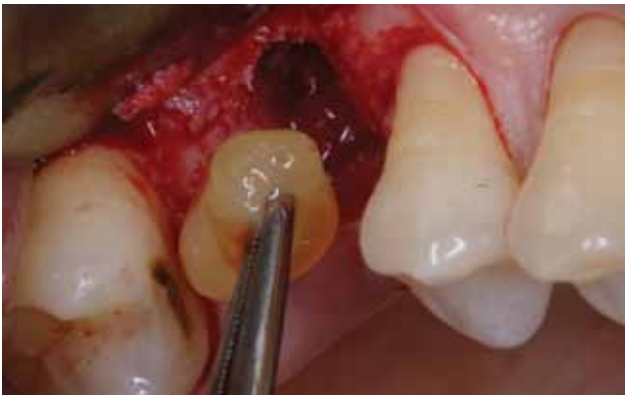

Figure 9: One piece of CGF was inserted under the elevated sinus membrane to accelerate new bone formation.

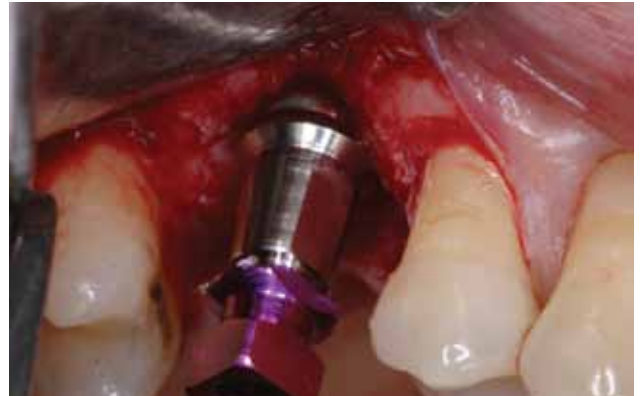

Figure 10: Note horizontal and vertical defect after implant placement.

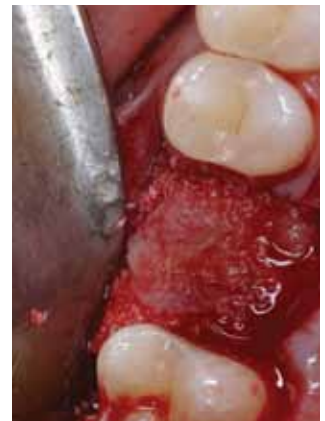

Figure 11: Bovine bone was grafted and CGF barrier was covered on the graft to accelerate new bone formation in the extraction defect.

Postoperative standard radiogram showed about 6mm high elevation of sinus membrane from HPISE technique. (Fig 12)

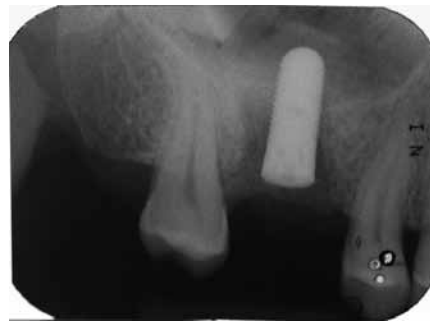

Figure 12: Radiogram showing 6 mm high sinus augmentation by HPISE technique.

Implant was uncovered after 14 weeks healing. Well augmented ridge was seen in the extraction socket even though the healing period was not enough. (Fig 13). Impression was taken on the same day and provisional crown was seated after 10 days for guided soft tissue healing. Final prosthesis was cemented after 3 months. Standard periapical radiogram taken after 6 months in function showed favorable sinus augmentation with CGF alone in the sinus. (Fig 13 - 15)



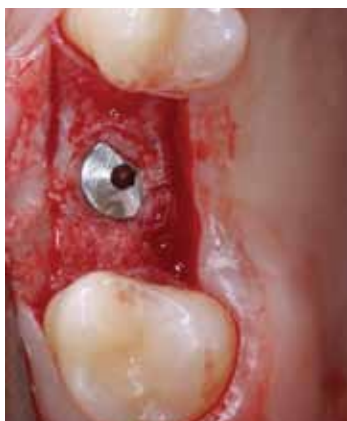

Figure 12: Note excellent bone regeneration after short healing period.

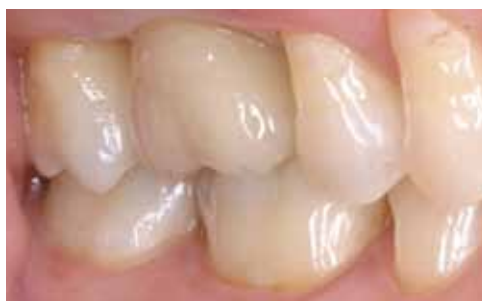

Figure 14: Final prosthesis.

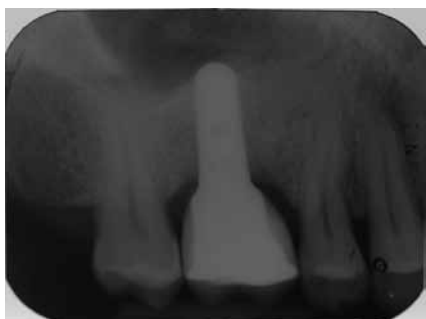

Figure 15: Radiogram showing favorable sinus augmentation with CGF alone after 6 months in function .

**2. Case report 2 : The use of CGF barrier membrane for guided tissue regeneration**

56 aged male complained a discomfort and pus discharge at #11. He wanted implant surgery but my treatment was to save this tooth using periodontal surgery and bone graft. Periapical radiogram showed severe alveolar bone resorption of #11. (Fig 16 & 17)

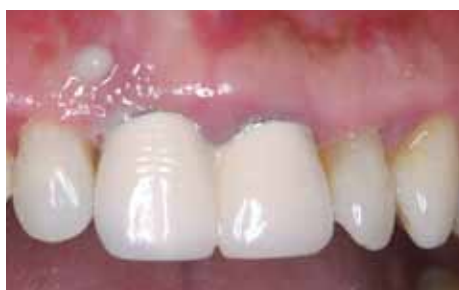

Figure 16: Pus was discharged at # 11.

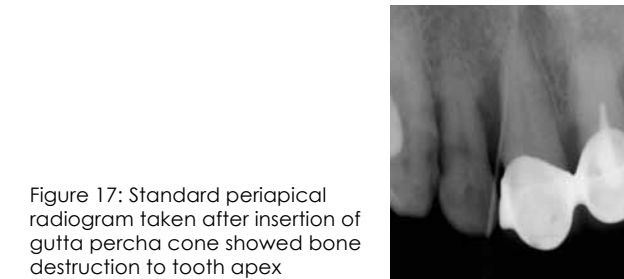


Figure 17: Standard periapical radiogram taken after insertion of gutta percha cone showed bone destruction to tooth apex

Two pieces of CGF was prepared before surgery. One piece was mixed with allograft (Allotis®, Bio-Tis bone Bank, Korea) to accelerate new bone formation and the other was used as barrier membrane. Both central incisors were exposed after local anesthesia and root panning was performed. (Fig 18 & 19)

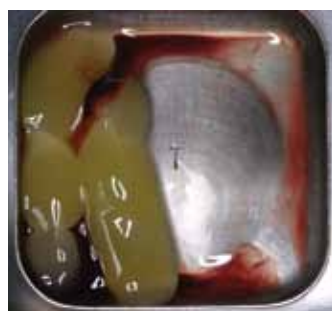

Figure 18: 2 pieces of CGF taken from 20cc patient's venous blood.

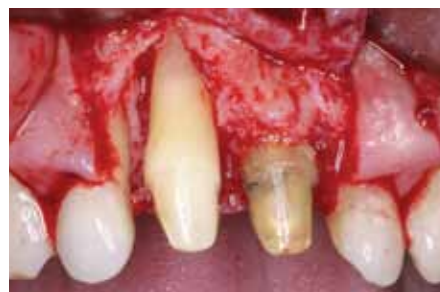

Figure 19: Root planning was performed to remove calculus and inflammatory tissue at #11.

Allograft mixed with CGF was grafted in the infrabony pocket and CGF barrier was cover the on the graft to accelerate new bone regeneration and soft tissue healing. Pocket depth was diminished after 5 months healing and bone regeneration was observed in the radiogram. (Fig 20-23)

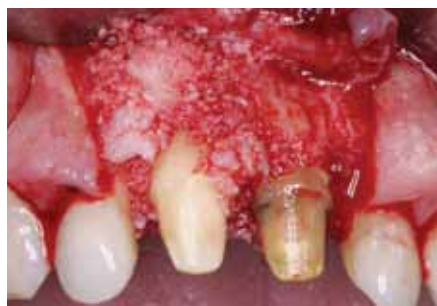

Figure 20: Allograft mixed with CGF was grafted in the periodontal defect.

Figure 21: CGF barrier membrane was covered on the bone graft to exclude soft tissue ingrowth and accelerate bone regeneration and soft tissue healing.

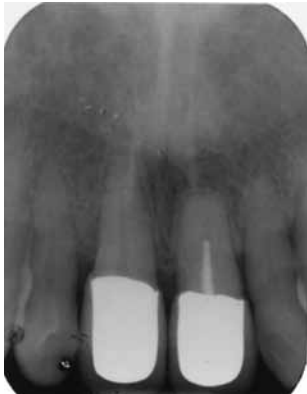
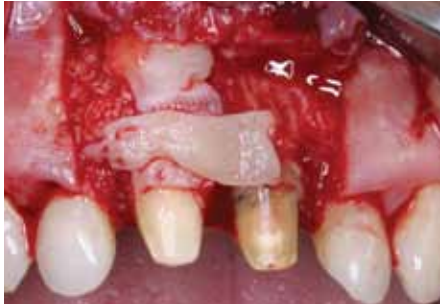
Figure 22: Radiogram showing periodontal regeneration in 5 months healing.

**3. Case report 3 : The use of CGF for GBR to accelerate bone formation**

65 aged woman visited at our department for implant surgery to replace the missing #36 and #37. Same surgical preparation was performed as that of case report I. Osteotomy was done for implant placement and cortical perforation was performed for blood supply to bone graft. Two Implants (Legacy implant, Implant Direct LLC, USA), were placed at the #36 and 337 site. Bone graft was essential to augment the narrow ridge. CGF was obtained before surgery. Three pieces of CGF was transformed to CGHF barrier membrane. Other was mixed with mineral allograft to accelerate bone formation and to make gel conditioned bone graft. (Fig 23 - 26)

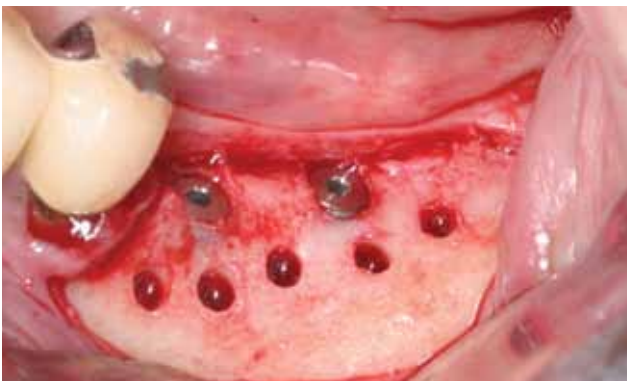


Figure 23: Note narrow ridge after implant placement.

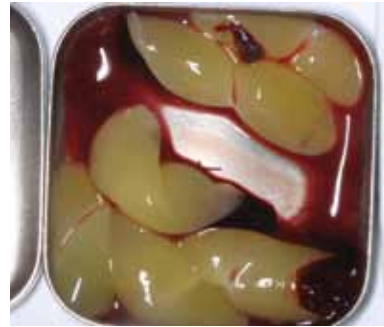

Figure 24: 6 pieces of CGF was prepared before surgery

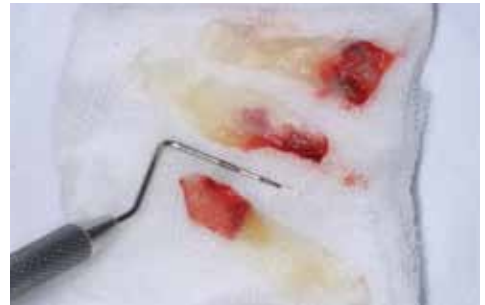

Figure 25: CGF barrier membrane.

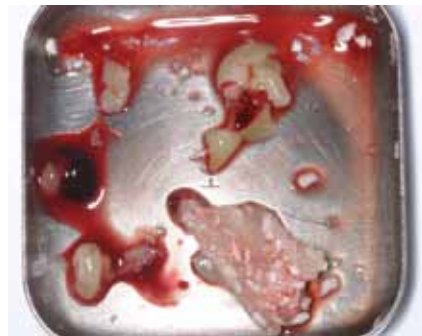


Figure 26: Allograft mixed with CGF.

Allograft mixed with CGF was grafted to augment the narrow alveolar ridge. Thanks to gel conditioned bone graft, bone graft maintained the shape; This was beneficial for space maintenance. Three pieces of CGF barrier were covered on the bone graft to exclude soft tissue ingrowth into the bone graft and to accelerate new bone formation and soft tissue healing. After only 12 weeks healing, implants were exposed and excellent bone regeneration was gained.

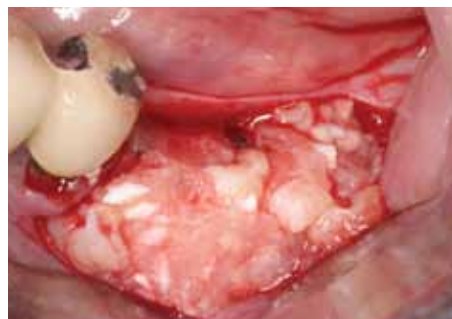

Figure 27: The mixture of allograft and CGF was grafted to augment the thin alveolar ridge.



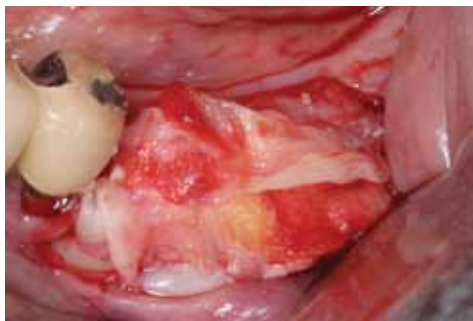

Figure 27: CGF barriers were covered on the bone graft.

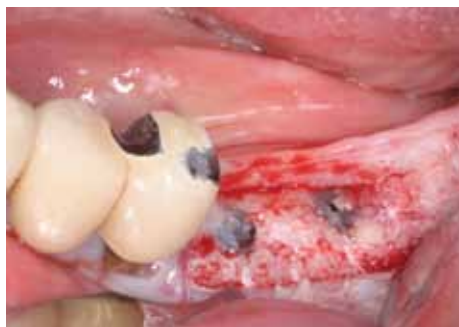
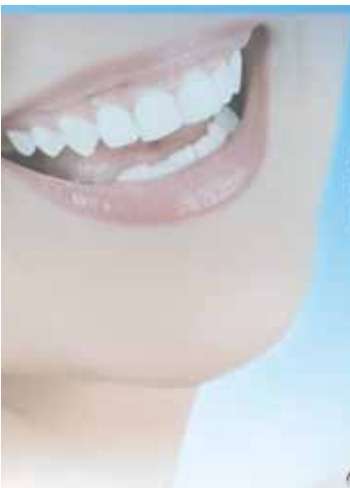
Figure 29: Note excellent ridge augmentation after 12 weeks healing.

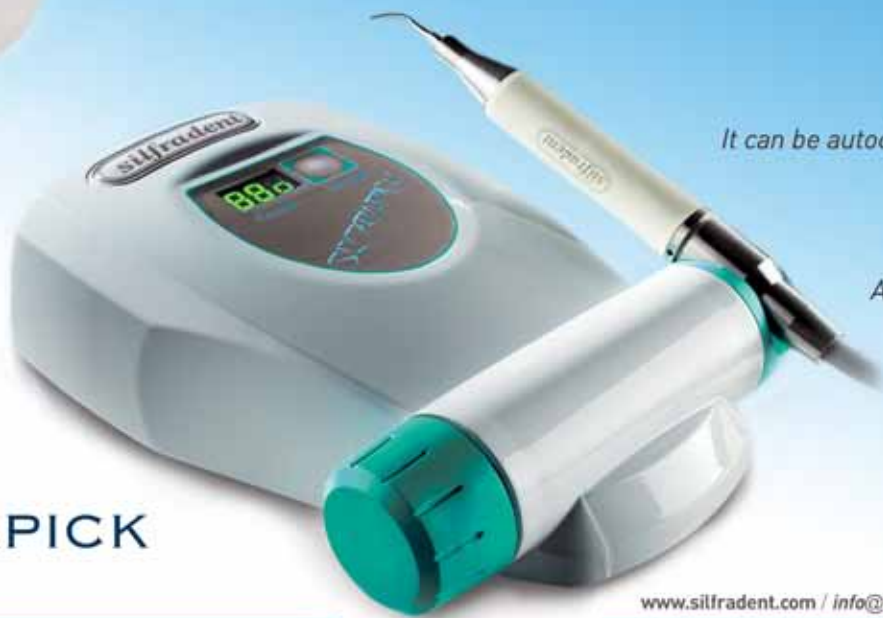## Result and Discussion

Growth factors play a major role to repair or generate damaged tissue. Most of growth factors are in blood plasma and platelet. So platelet concentrates contains sufficient growth factors such as platelet-derived growth factors(PDGF), transforming growth factor(TGF- $\beta$ ), Insulin-like growth factor(IGF-I), epidermal growth factor(EGF), vascular endothelial growth factor(VEGF), basic fibroblast growth factor(bFGF).<sup>15</sup> PRP as platelet aggregates was first introduced by Marx et al.<sup>9</sup> PRP has widely been used in the dental field such as sinus augmentation, ridge augmentation, periodontal regeneration and soft tissue healing. However the effect of PRP is controversial. According to one systemic review on the effect of PRP, The beneficial effects of PRP in the treatment of periodontal defects is evident but evidence for beneficial effects of PRP in sinus elevation appeared to be weak.<sup>10</sup>



**Silfradent Medical Line**  
for Advanced Italian Technology

**THE THOUGHT OF THE DENTIST  
BRINGS A BROAD SMILE**



**UL 100M:** Titanium handpiece with unique waterproof system. It can be autoclaved at a temperature of 134° C.

Ultrasonic piezo-scaler: powerful and gentle. Adjustable power delivery between 5% and 95% for scaling and endo function.


**SILFRAPICK  
UL 100**

[www.silfradent.com](http://www.silfradent.com) / [info@silfradent.com](mailto:info@silfradent.com)



PRP and PRGF extract platelet concentrates using pipetting after centrifugation of venous blood in the dental office. The procedure has the possibility of technical error to extract proper platelet concentrates. They use only 10% of acquired blood. This could be the waste of patient's blood. PRF and CGF overcome these disadvantages of PRP and PRGF. Unlike PRP and PRGF, PRF and CGF do not require any chemical and biochemical additives. They use 30-40% of acquired venous blood. CGF is known to have higher tensile strength, higher growth factors and higher viscosity than PRF, so compressed CGF can be used barrier membrane with growth factors as alternative collagen membrane. This barrier induces faster formation and soft tissue healing. When it is mixed with bone graft, faster bone formation can be obtained as seen in this case report. When CGF is applied to donor site of connective tissue graft, it reduces pain and inflammation and bleeding tendency. In addition, faster soft tissue healing can be obtained. CGF can be applied sinus augmentation. Sinus augmentation with CGF alone was reported successfully within 4 month healing period. CGF can be used sinus augmentation as alternative to bone substitutes in this report.<sup>16</sup>

## Conclusion

CGF barrier is effective to regenerate bone formation associated with GBR and GTR procedure. In addition, the mixture of CGF and bone graft could reduce healing time compared to conventional GBR procedure. When applying CGF alone for internal sinus elevation, CGF may accelerate new bone formation in the new compartment of maxillary sinus. 

## ABOUT THE EXPERT

**Dong-Seok Sohn**, is Professor and Chair, Department of oral and maxillofacial surgery, at Catholic University of Daegu, School of Medicine, Daegu, Korea. He is the first introducer of SurgyBone (Silfradent, Italy) Piezosurgery (Mectron, Italy), and UBS (ItaliaMedica, Italy) in Asia Pacific Area and developer of innovative Hydrodynamic Piezo electric Internal elevation. He is co-recipient of 2007 Charles English Award by Implant Dentistry which is flagship journal of ICOI.



## REFERENCES

- 1 Dahlin C, Linde A, Gottlow J, Nyman S. Healing of bone defects by guided tissue regeneration. *Plast Reconstr Surg.* 1988 May; 81(5):672-676.
- 2 Haney JM, Nilveus RE, McMillan PJ, Wikesjo UM Periodontal repair in dogs: expanded polytetrafluoroethylene barrier membranes support wound stabilization and enhance bone regeneration. *J Periodontol* 1993 Sep;64(9):883-890
- 3 "PASS" principles for predictable bone regeneration. Wang HL, Boyapati L. *Implant Dent.* 2006 Mar;15(1):8-17
- 4 Marx RE. Platelet-rich plasma (PRP): what is PRP and what is not PRP?. *Implant Dent* 2001;10(4):225-228
- 5 Anitua E. Plasma rich in growth factors: preliminary results of use in the preparation of future sites for implants. *Int J Oral Maxillofac Implants.* 1999 Jul-Aug;14(4):529-535
- 6 Dohan DM, Choukroun J, Diss A, Dohan SL, Dohan AJ, Mouhyi J, Gogly B. Platelet-rich fibrin (PRF): a second-generation platelet concentrate. Part I: technological concepts and evolution. *Oral Surg Oral Med Oral Pathol Oral Radiol Endod.* 2006 Mar;101(3):e37-44. Epub 2006 Jan 19
- 7 Sacco L. Lecture, International academy of implant prosthesis and osteoconnection, 2006. 12. 4.
- 8 Clark RA. Fibrin and wound healing. *Ann N Y Acad Sci.* 2001;936:355-67.
- 9 Marx RE, Carlson ER, Eichstaedt RM, Schimmele SR, Strauss JE, Georgeff KR. Platelet-rich plasma: Growth factor enhancement for bone grafts. *Oral Surg Oral Med Oral Pathol Oral Radiol Endod.* 1998 Jun;85(6):638-46.
- 10 Plachokova AS, Nikolidakis D, Mulder J, Jansen JA, Creugers NH. Effect of platelet-rich plasma on bone regeneration in dentistry: a systematic review. *Clin Oral Implants Res.* 2008 Jun;19(6):539-45
- 11 Anitua E. The use of plasma-rich growth factors (PRGF) in oral surgery. *Pract Proced Aesthet Dent.* 2001 Aug;13(6):487-93
- 12 Choukroun J, Adda F, Schoeffler C, Vervelle A. Une opportunit  en paro-implantologie: le PRF. *Implantodontie* 2000;42:55-62. French.
- 13 Choukroun J, Diss A, Simonpieri A, Girard MO, Schoeffler C. Platelet-rich fibrin (PRF): a second-generation platelet concentrate. Part IV: clinical effects on tissue healing. *Oral Surg Oral Med Oral Pathol Oral Radiol Endod.* 2006 Mar;101(3):e56-60.
- 14 Choukroun J, Diss A, Simonpieri A, Girard MO, Schoeffler C, Dohan SL, Dohan AJ, Mouhyi J, Dohan DM Platelet-rich fibrin (PRF): a second-generation platelet concentrate. Part V: histologic evaluations of PRF effects on bone allograft maturation in sinus lift. *Oral Surg Oral Med Oral Pathol Oral Radiol Endod.* 2006 Mar;101(3):299-303.
- 15 Marx RE. Platelet-rich plasma: Evidence to support its use. *J Oral maxillofac Surg.* 2004;62:489-496
- 16 Sohn DS, Moon JW, Moon YS, Park JS, Jung HS. The use of concentrated growth factors (CGF) for sinus augmentation. *Implant Journal(Japan).* 2009;38:25-35